MERCK MANUAL
Professional Version

Schistosomiasis

(Bilharziasis)

*By **Chelsea Marie**, PhD, University of Virginia;*
***William A. Petri, Jr**, MD, PhD, University of Virginia School of Medicine*

Reviewed/Revised Aug 2023

Schistosomiasis is infection with blood flukes of the genus *Schistosoma*, which are acquired transcutaneously by swimming or wading in contaminated freshwater. The organisms infect the vasculature of the gastrointestinal or genitourinary system. Acute symptoms are dermatitis, followed several weeks later by fever, chills, nausea, abdominal pain, diarrhea, malaise, and myalgia. Chronic symptoms vary with species but include bloody diarrhea (eg, with *S. mansoni*, *S. mekongi*, *S. intercalatum*, and *S. japonicum*) or hematuria (eg, with *S. haematobium*). Diagnosis is by identifying eggs in stool, urine, or biopsy specimens. Serologic tests may be sensitive and specific but do not provide information about the worm burden or clinical status. Treatment is with praziquantel.

Flukes are parasitic flatworms that infect various parts of the body (eg, blood vessels, gastrointestinal tract, lungs, liver) depending on the species.

See also the World Health Organization (WHO) and Centers for Disease Control and Prevention (CDC) information on schistosomiasis.

Etiology of Schistosomiasis

Schistosomiasis is by far the most important trematode infection. *Schistosoma* is the only trematode that invades through the skin; all other trematodes infect only via ingestion. Over 200 million people are infected worldwide (see CDC: About Schistosomiasis).

Five species of schistosomes infect humans; all have similar life cycles involving freshwater snails. *S. haematobium* causes urinary tract disease; the other *Schistosoma* species cause intestinal disease.

Geographic distribution of schistosomes that infect humans differs by species:

- *S. haematobium:* Widely distributed over the African continent with smaller foci in the Middle East, Turkey, and India
- *S. mansoni:* Widespread in Africa, foci in Middle East, and the only species in the Western Hemisphere in parts of South America and some Caribbean islands

- *S. japonicum:* Asia, mainly in China, the Philippines, Thailand, and Indonesia
- *S. mekongi:* Southeast Asia
- *S. intercalatum:* Central and West Africa

Humans are the main reservoir of infection. Dogs, cats, rodents, pigs, horses, and goats are reservoirs for *S. japonicum*, and dogs are reservoirs for *S. mekongi*. Transmission of these species does not occur within the United States (including Puerto Rico) and Canada, but the disease may be present in travelers and immigrants from endemic areas.

Pathophysiology of Schistosomiasis

Adult *Schistosoma* worms live and copulate within venules of the mesentery (typically *S. mekongi*, *S. intercalatum*, *S. japonicum* and *S. mansoni*) or bladder (typically *S. haematobium*). Some eggs penetrate the intestinal or bladder mucosa and are passed in stool or urine; other eggs remain within the host organ or are transported through the portal system to the liver and occasionally to other sites (eg, lungs, central nervous system, spinal cord). Excreted eggs hatch in freshwater, releasing miracidia (first larval stage), which enter snails. After multiplication, thousands of free-swimming, forked-tailed cercariae are released.

Cercariae penetrate human skin within a few minutes after exposure. When they penetrate the skin, they lose their forked tail and transform into schistosomula, which travel through the bloodstream to the liver, where they mature into adults. The adults then migrate to their ultimate home in the intestinal veins or the venous plexus of the genitourinary tract.

Eggs appear in stool or urine 1 to 3 months after cercarial penetration.

Estimates of the adult worm life span range from 3 to 7 years. The females range in size from 7 to 20 mm; males are slightly smaller.

Symptoms and Signs of Schistosomiasis

Acute schistosome dermatitis

Most infections are asymptomatic. A pruritic papular rash (cercarial dermatitis) can develop where cercariae penetrate the skin.

Acute Katayama fever

Katayama fever is a systemic hypersensitivity reaction that may occur with onset of egg laying, typically 2 to 4 weeks

***Schistosoma* Life Cycle**

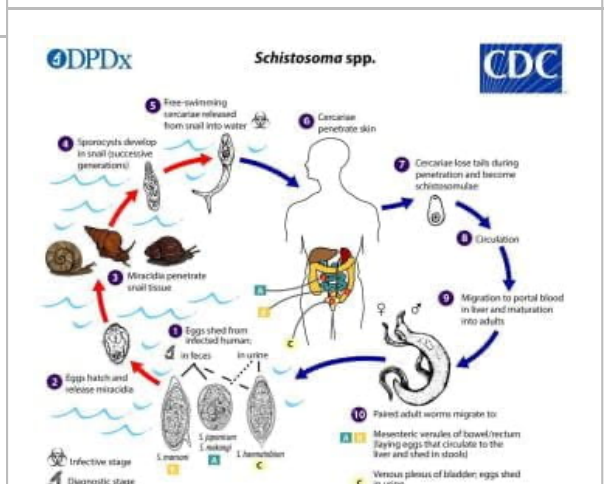

after heavy exposure. Symptoms include fever, chills, cough, nausea, abdominal pain, malaise, myalgia, urticarial rashes, and marked eosinophilia, resembling serum sickness. Manifestations are more common and usually more severe in visitors than in residents of endemic areas and typically last for several weeks.

IMAGE FROM THE CENTERS FOR DISEASE CONTROL AND PREVENTION, GLOBAL HEALTH, DIVISION OF PARASITIC DISEASES AND MALARIA.

Chronic schistosomiasis

Chronic infection is most commonly due to repeated exposure in endemic areas but can also occur after brief exposure such as occurs in travelers. Chronic schistosomiasis results primarily from granulomatous host responses to eggs retained in tissues.

Intestinal schistosomiasis: Early on, intestinal mucosal ulcerations caused by *S. mansoni*, *S. japonicum*, *S. mekongi*, or *S. intercalatum* may bleed and result in bloody diarrhea. As lesions progress, focal fibrosis, strictures, fistulas, and papillomatous growths may develop in the intestine.

Hepatosplenic schistosomiasis: Granulomatous reactions to eggs of *S. mansoni*, *S. japonicum*, *S. mekongi*, and *S. intercalatum* in the liver usually do not compromise liver function, but they may cause fibrosis and cirrhosis, which can lead to portal hypertension, resulting in splenomegaly, and esophageal varices. Esophageal varices may bleed, causing hematemesis.

Eggs in the lungs may produce granulomas and focal obliterative arteritis, which may ultimately result in pulmonary hypertension and cor pulmonale.

Bladder involvement with *S. haematobium* produces ulcerations in the bladder wall that may cause dysuria, hematuria, and urinary frequency. Over time, chronic cystitis develops. Strictures may lead to hydroureter and hydronephrosis. Papillomatous masses in the bladder are common, and squamous cell carcinoma of the bladder may develop.

Genital schistosomiasis in young girls and women can involve the vulva, vagina, and cervix as well as the fallopian tubes. Genital schistosomiasis can result in vaginal bleeding during sex and gynecologic examinations, pain during sex, infertility, ectopic pregnancy, abortion, and increased risk of acquiring HIV infection (1). Male genital involvement of the epididymis, testicles, spermatic cord, or prostate can result in pelvic, coital, or ejaculatory pain, hematospermia, abnormal swelling of genital organs, and infertility.

Blood loss from both gastrointestinal and genitourinary tracts frequently results in iron-deficiency anemia.

Secondary bacterial infection of the genitourinary tract is common with *Salmonella*, and persistent or recurrent infection may occur. Neurologic complications can occur even in light *Schistosoma* infections. Eggs or adult worms lodged in the spinal cord can cause transverse myelitis, and those in the brain can produce focal lesions and seizures.

Symptoms and signs reference

Symptoms and signs reference

1. Orish VN, Morhe EKS, Azanu W, et al: The parasitology of female genital schistosomiasis. *Curr Res Parasitol Vector Borne Dis* 2:100093, 2022. Published 2022 May 27. doi:10.1016/j.crpvbd.2022.100093

Diagnosis of Schistosomiasis

- Microscopic examination of stool or urine (*S. haematobium*) for eggs
- Antigen tests
- Serologic tests

Diagnostic testing is indicated for patients with symptoms of schistosomiasis and relevant epidemiologic exposure. Screening of asymptomatic people may be warranted for those exposed to fresh water in endemic areas.

Schistosomiasis is diagnosed and parasite burden is estimated by microscopic examination of stool or urine (*S. haematobium*) for eggs. Repeated examinations using concentration techniques may be necessary. Geography is a primary determinant of species, so the location of exposure should be communicated to the laboratory. If the clinical picture suggests schistosomiasis but no eggs are found after repeated examination of urine or feces, intestinal or bladder mucosa can be biopsied to check for characteristic granulomas around embedded eggs.

Tests for schistosomal antigens or DNA in blood, urine, or stool are particularly useful for schistosome eradication programs and in returning travelers with suspected infection. Most antigen detection tests are quantitative and antigen levels are correlated to parasite burden. Some antigen tests, such as the commercially available urine dipstick for *S. mansoni*, are qualitative.

Serologic tests are sensitive and specific for infection, but do not provide information about worm burden, clinical status, or prognosis and do not distinguish active from resolved infection. Antibody tests thus are most useful for detecting infection in returning travelers and not helpful in patients who are residents of endemic areas. With returning travelers, serologic tests should be done ≥ 6 to 12 weeks after the last exposure to fresh water to allow time for maturation of the schistosomes into adults and for development of antibodies.

Hepatosplenic schistosomiasis can be diagnosed by finding eggs in stool, intestinal tissue, or liver samples taken for biopsy with variable sensitivity as egg shedding can be intermittent in such patients. Typically, liver blood tests are normal. Ultrasonography may show periportal fibrosis and splenomegaly.

Neuroschistosomiasis is diagnosed if there is infection at an extraneural site along with clinical and radiographic evidence of neurologic involvement. Schistosomes in biopsied central nervous system lesions, and/or a positive antibody test or polymerase chain reaction in cerebrospinal fluid are also diagnostic.

Treatment of Schistosomiasis

- Praziquantel

Single-day oral treatment with praziquantel (20 mg/kg twice a day for *S. haematobium*, *S. mansoni*, and *S. intercalatum*; 20 mg/kg 3 times a day for *S. japonicum* and *S. mekongi*) is recommended. Praziquantel is effective against adult schistosomes, but not developing schistosomula, which are present early in infection. Thus, for asymptomatic travelers who have had exposure in potentially contaminated fresh water, treatment is delayed for 6 to 8 weeks after the last exposure. Adverse effects of praziquantel are generally mild and include abdominal pain, diarrhea, headache, and dizziness. Therapeutic failures have been reported, but it is difficult to determine whether they are due to reinfection, the relative resistance of immature schistosomes, or praziquantel-resistant adult schistosomes.

If eggs are present at the time of diagnosis, follow-up examination 1 to 2 months after treatment is suggested to help confirm cure. Treatment is repeated if eggs are still present.

Treatment of acute schistosomiasis (Katayama fever) is based on limited data. Corticosteroids can ameliorate severe symptoms; treatment with prednisone 20 to 40 mg daily for 5 days in adults is usually effective. Once symptoms have subsided, treatment with praziquantel is given as detailed above and repeated 4 to 6 weeks later after parasites have reached adulthood.

Patients with eggs in stool or urine at the time acute or chronic schistosomiasis is diagnosed should be examined for living eggs 1 to 2 months after treatment. An experienced microscopist can distinguish viable eggs from empty shells based on the presence of living miracidium. Retreatment is indicated if viable eggs are present.

Prevention of Schistosomiasis

Scrupulously avoiding contact with contaminated fresh water prevents schistosomiasis.

Schistosomiasis is not transmitted by swallowing contaminated water; however, mouth and lip contact with contaminated water could lead to infection.

Fresh water used for bathing should be boiled for at least 1 minute and then cooled before bathing. However, water that has been held in a storage tank for at least 1 to 2 days should be safe without boiling.

People who are accidentally exposed to possibly contaminated water (eg, by falling into a river) should vigorously dry off with a towel to attempt to remove any parasites before they penetrate the skin.

The sanitary disposal of urine and feces reduces the likelihood of infection.

Adult residents of endemic areas are more resistant to reinfection than children, suggesting the possibility of acquired immunity.

Mass community-based or school-based treatment with praziquantel, education programs, and

Mass community-based or school-based treatment with praziquantel, education programs, and molluscicides to reduce snail populations are used to control schistosomiasis in endemic areas.

Vaccine development is under way.

Key Points

- ***Schistosoma*** **is the only trematode that invades through the skin; over 230 million people are infected worldwide.**
- **When cercariae penetrate the skin, they lose their forked tail and become schistosomula, which travel through the bloodstream to the liver, where they mature; as adults, they migrate to their ultimate home in the intestinal veins or the venous plexus of the genitourinary tract.**
- **Ova in the liver trigger a granulomatous reaction that can lead to fibrosis and portal hypertension, resulting in splenomegaly, esophageal varices, and hematemesis.**
- **Organisms in the intestine can cause bloody diarrhea, and organisms in the bladder can cause hematuria and chronic cystitis.**
- **Treat with praziquantel.**
- **To prevent infection, avoid contact with fresh water in endemic areas.**

Dermatitis Caused by Avian and Animal Schistosomes

Cercarial dermatitis, a skin condition that also may be called clam digger's itch or swimmer's itch, occurs when *Schistosoma* species that cannot develop in humans penetrate the skin during contact with contaminated fresh water or brackish water.

Cercariae of *Schistosoma* species that infect birds and mammals other than humans can penetrate human skin. Although the organisms do not develop in humans, humans may become sensitized and develop pruritic maculopapular or vesicular skin lesions at the site of penetration. Skin lesions may be accompanied by a systemic febrile response that runs for 5 to 7 days and resolves spontaneously.

Cercarial dermatitis occurs worldwide. In North America, ocean-related schistosome dermatitis (clam digger's itch) occurs on all Atlantic, Gulf, Pacific, and Hawaiian coasts. It is common in muddy flats off Cape Cod. Freshwater schistosome dermatitis (swimmer's itch) is common in the Great Lakes region.

Diagnosis of cercarial dermatitis is based on clinical findings. Most cases do not require medical

attention.

Treatment of cercarial dermatitis is symptomatic with cool compresses, baking soda, or antipruritic lotions. Topical corticosteroids can also be used.

Drugs Mentioned In This Article

Copyright © 2023 Merck & Co., Inc., Rahway, NJ, USA and its affiliates. All rights reserved.